Substantiating the Use of Ultrasound Tissue Characterization in the Analysis of Tendon Structure: A Systematic Review

Lucas Maciel Rabello, MSc,* Olivier Christian Dams, BSc,* Inge van den Akker-Scheek, PhD,*† Johannes Zwerver, PhD,* and Seth O'Neill, PhD‡

Abstract

Objective: To determine the role of ultrasound tissue characterization (UTC) in predicting, diagnosing, and monitoring tendon structure and/or tendinopathy. In addition, this study aims to provide recommendations for standardized methodology of UTC administration and analysis. **Data Source:** The PubMed, Embase, and Web of Science databases were searched (up to September 2018). All scientific literature concerning the use of UTC in assessing tendons was collected. The initial search resulted in a total of 1972 hits, and after screening by eligibility criteria, 27 articles were included. **Results:** In total, 18 investigating the Achilles tendon, 5 the patellar tendon, and 4 both Achilles and patellar tendons were included. The methods of UTC administration and analysis differed and were not uniform. The studies showed that the use of UTC to predict Achilles tendinopathy (AT) is inconclusive, but that a higher amount of tendon disorganization increases the risk of developing patellar tendinopathy (PT). In terms of diagnosis, UTC might provide additional information in AT cases. In addition, promising results were found for the use of UTC in both AT and PT in monitoring the effect of load or treatment on tendon structure. **Conclusion:** More research regarding the use of UTC in predicting tendon pathology is required. Ultrasound tissue characterization seems useful as an adjunct diagnostic modality because it can be used to differentiate symptomatic from asymptomatic tendons. In addition, UTC is a promising device to be used to monitor changes in tendon structure in response to load or treatment. Moreover, we provide recommendations of a standardized protocol concerning the methods of UTC measurement and analysis.

Key Words: tendinopathy, ultrasound, Achilles tendon, patellar tendon

(*Clin J Sport Med* 2021;31:e161–e175)

INTRODUCTION

The Achilles and the patellar tendons are 2 of the strongest tendons in the human body and thus subjected to large and frequent weight-bearing forces.[1,2] As a result of this loading, these tendons are prone to overuse injuries such as tendinopathy, occurring in both (recreational) athletes[3] and sedentary individuals.[4] The prevalence of Achilles tendinopathy (AT) and patellar tendinopathy (PT) is estimated at approximately 2.35 and 1.60 per 1000 in the general population,[5] and even higher in competitive athletes,[6] and these numbers are expected to rise because of increasing (recreational) sport participation, especially in the middle-aged athletes.[7]

Tendinopathy causes significant (functional) impairment and may be career ending for athletes.[8] In addition, tendinopathy is difficult to treat, and many patients fail to respond to treatment.[2] It has been proposed that tendinopathy can eventually lead to rupture of the tendon,[9–11] further worsening the prognosis regarding tendon function and participation in sporting activities.

The diagnosis of tendinopathy is usually clinical, but it can be confirmed with imaging, such as ultrasound (US) or magnetic resonance imaging. However, there seems to be a poor correlation between imaging results and patient-reported symptoms.[12,13] This makes it difficult for clinicians to monitor treatment and to predict athlete's (future) risk of tendinopathy. A systematic review by McAuliffe et al concluded that US may be useful in predicting future tendinopathy,[14] although US poses problems such as interoperator variance, variations in transducer positioning, and lack of standardization.

van Schie et al[15] attempted to address these issues by introducing the imaging modality ultrasound tissue characterization (UTC). Ultrasound tissue characterization is an ultrasonographic imaging modality that consists of a 10-MHz linear array transducer fitted to a tracking device that automatically takes 600 images in transverse plane at intervals of 0.2 mm along the tendon constructing a 3-dimensional data block.[15] These recordings can be analyzed by quantification and calculation of the percentage of echo types of a specific portion of the tendon tissue. These echo types (I-IV) represent tendon integrity and fibrillar disorganization: (I) highly stable, (II) medium stable, (III) highly variable, and (IV) constantly low intensity and variable distribution.[15] This imaging tool is only validated in the equine tendon; however, since 2010, the UTC has been widely used in the investigation of the human tendon.[16]

Submitted for publication December 1, 2018; accepted March 19, 2019.

*From the Departments of *Sports and Exercise Medicine; and †Orthopedics, University of Groningen, University Medical Center Groningen, Groningen, the Netherlands; and ‡Department of Life Sciences, School of Allied Health Professions, University of Leicester, Leicester, United Kingdom.*

L. Maciel Rabello is supported by CNPq, National Council for Scientific and Technological Development—Brazil. The remaining authors report no conflicts of interest.

Corresponding Author: Lucas Maciel Rabello, MSc, Department of Sports and Exercise Medicine, University Medical Center Groningen, PO box 30.001, 9700 RB Groningen, the Netherlands (rabello.lm@gmail.com).

Copyright © 2019 Wolters Kluwer Health, Inc. All rights reserved.

http://dx.doi.org/10.1097/JSM.0000000000000749

Copyright © 2019 Wolters Kluwer Health, Inc. Unauthorized reproduction of this article is prohibited.

Ultrasound tissue characterization can discriminate symptomatic from asymptomatic tendons.[15] However, the role of UTC in diagnosing, predicting, and monitoring tendon structure and/or tendinopathy is still relatively unknown. In addition, despite the potential UTC has in quantifying tendon structure, no conclusive guidelines exist for either the scanning of tendons or analyzing of the images. This has led to large variations in scanning and reporting of UTC imaging. There are currently several variations of scanning methods using different patient, ankle/knee, and tracker positions, as well as scanning directions that may impact reliability and/or validity of reported findings. In addition to the methods of scanning, there are large variations in the methodology used for the image analysis: The main variations appear to be the window size (number of frames the pixel brightness and stability pattern are based on, variations in this impact the percentage of the different echo types) and the length of tissue the quantification is based on, entire tendon or small section. Because UTC is not yet standard clinical practice, it is hypothesized that the methods of administration vary and lack uniformity, and this impacts the research conclusions.

This study aims to determine the role of UTC in predicting, diagnosing, and (treatment progress) monitoring tendon structure and/or tendinopathy by systematically reviewing all available literature relating to UTC administration and/or analysis of tendons. In addition, this study aims to provide recommendations for standardized methodology of UTC administration and analysis.

METHODS

This systematic review was conducted according to the PRISMA-Protocol for Systematic reviews.[17]

Search Strategy and Criteria

A systematic electronic search using the databases PubMed, Embase, and Web of Science was performed in September 2018. All scientific literature concerning the use of UTC in the human tendon (injuries) was collected. Implementation and validation of the search terms and search methods were attained from a medical librarian at the University of Groningen. Search strategy is listed in Table 1.

Study Selection

Inclusion criteria were as follows: primary research studies using UTC to assess tendon structure. The exclusion criteria were as follows: reviews, case studies, and animal studies. There was no language restriction.

Data Extraction and Analysis

Two reviewers were involved in the study selection process. Two reviewers (L.M.R. and O.C.D.) independently selected the studies by applying the inclusion and exclusion criteria in 3 successive rounds. In the first round, reviewers screened the titles followed by the abstract selection. In the third round, the full text was screened. In case of disagreement between the 2 reviewers in any of the rounds, a third opinion (I.v.d.A.-S.) was requested.

The following data were extracted from the full texts of the included articles:

1. Study information: author(s), year, and design;
2. Subject information: characteristics, tendon, tendinopathy, and follow-up;
3. Ultrasound tissue characterization scanning methodology: patient position (prone, supine, sitting, or standing), direction of the scan (proximal or distal), window size (9, 17, or 25), and area of the tendon analyzed;
4. Ultrasound tissue characterization's clinical role in predicting, diagnosing, and monitoring tendon structure and/or tendinopathy, UTC results, and practical recommendations for UTC application. The following were the definitions used:
   - Predicting: UTC use before or until the development of tendinopathy;
   - Diagnosis: UTC use to show structure and pathology; cross-sectional design;
   - Monitoring: UTC use longitudinally to assess tendon structure in response to a stimulus (eg, treatment and load).

RESULTS

Search Results

The applied search yielded 1351 articles (Figure 1). Of these articles, 27 met our inclusion criteria. The methods of UTC administration are presented in Table 2. The other extracted data are presented in Table 3. Eighteen studies performed a scan of the Achilles tendon,[15,18–34] 5 of the patellar tendon,[35–39] and 4 studies assessed both.[40–43] No publications regarding the use of UTC in other tendons were found. Most studies concerned patients with (a history of) Achilles mid-portion tendinopathy.

Ultrasound Tissue Characterization Methods

Generally, studies used 1 of 2 positions to perform the scan of the Achilles tendon: the standing position[18,24,25,29,30,34,40,43] and the prone position.[15,19–23,27,28,31,33,41,42] Of the studies

TABLE 1. Search Strings by Database

Database	Search String
PubMed	("Achilles Tendon"[Mesh] OR achilles tend*[tw] OR ((achill*[tw] OR patella*[tw]) AND ("Tendinopathy"[Mesh] OR tendonit*[tw] OR tendinit*[tw] OR tendinos*[tw] OR rupture [tw] OR tear [tw] OR tendinopath*[tw] OR tendon*[tw]))) AND (UTC [tw] OR echotype* [tw] OR (tissue[tw] AND characteri* [tw]) OR (ultraso*[tw] AND characteri*[tw])) NOT ("Animals"[Mesh] NOT "Humans"[Mesh])
Embase	("Achilles tendon"/exp OR" "achilles tendinitis"/exp OR achillodyn*:ab,ti,de OR ((achill* OR patella*) NEAR/3 (tendino* OR tendini* OR tendon* OR rupture OR tear)):ti,ab,de) AND (UTC OR echotype* OR (tissue AND characteri*) OR (ultraso* AND characteri*)):ab,ti,de NOT ("animal"/exp NOT "human"/exp)

Copyright © 2019 Wolters Kluwer Health, Inc. Unauthorized reproduction of this article is prohibited.

TABLE 2. Methods of Ultrasound Tissue Characterization Administration

Author	Patient Position	Direction of the Scan	Side	Window Size	Region of Interest (ROI)	
					Area Analyzed	Interval Between Contours
Docking et al[41]	Achilles: prone with their feet off the edge of a plinth in 90 degrees of ankle dorsiflexion	From proximal to distal	Unilateral or bilateral	25	Achilles: from the disappearance of the calcaneus to the appearance of the musculotendinous junction	Not described
	Patellar: supine with their knee at 120-degree flexion				Patellar: from the disappearance of the inferior patella pole to 3 cm distally	
Docking et al[42]	Achilles: prone with their feet off the edge of a plinth in 90 degrees of ankle dorsiflexion	From proximal to distal	Unilateral	25	Achilles: from the disappearance of the calcaneus to the appearance of the musculotendinous junction	Not described
	Patellar: supine with their knee at 120-degree flexion				Patellar: from the disappearance of the inferior patella pole to 3 cm distally	
de Sá et al[21]	Prone on an examination bed with their feet placed on a foot and ankle stabilizer to stabilize and position the Achilles tendon	Not described	Bilateral	25	The examiner determined the landmark (2 cm from the calcaneal insertion) in the sagittal plane. Contours were drawn at 2 mm proximal and distal to the landmark (4 mm total)	4 mm
Rudavsky et al[37]	Supine position with the left knee flexed to 90 degrees	From proximal to distal	Unilateral	25	From the disappearance of the inferior pole of the patella, extending 1 cm distally	No more than 4 mm
van Ark et al[39]	Supine position with the left knee flexed to 100 degrees	From proximal to distal	Unilateral	25	From the disappearance of the inferior pole of the patella, extending 3 cm distally	No greater than 5 mm
Waugh et al[31]	Prone position with foot placed in stabilizer used achieves perpendicular alignment. UTC transducer placed at 5/10 degree dorsiflexion.	Not described	Bilateral	25	A scan 2.5 cm proximal of the insertion of the Achilles tendon was located. The Achilles tendon border was outlines 2 mm either side of this slice location in the sagittal plane and the 2 contours interpolated to create a 20 scans × 0.2 mm region of interest.	4 mm
Heyward et al[26]	Prone position with maximum ankle dorsiflexion	Distal to proximal	Unilateral	25	Achilles mid-portion (from 2 cm proximal to the upper border of the calcaneus in a proximal direction)	No greater than 5 mm
Rudavsky et al[36]	Supine position with the left knee flexed to 90 degrees	From proximal to distal	Unilateral	25	From the disappearance of the inferior pole of the patella, extending 2 cm distally	No more than 4 mm
Esmaeili et al[43]	Achilles: Standing on a raised level surface with the great toe and knee touching the wall in a standardized lunge position	Distal to proximal	Bilateral	25	Achilles: multiple contours (from the disappearance of the calcaneus to the musculotendinous junction	No greater than 5 mm
	Patellar: supine position, knee flexed at ~60 degrees.				Patella: over a distance of 3 cm starting from the disappearance of the inferior pole of the patella.	
Stanley et al[30]	Standing on a raised level surface with the great toe and knee touching the wall in a standardized lunge position	Distal to proximal	Unilateral	17	0.5 cm proximal to the insertion of the Achilles to the calcaneus, continuing to the musculotendinous junction or a length of 6 cm	0.5 mm (if necessary, more frequent contours were added)
Hernández G et al[35]	Sitting position with the foot placed in a high surface and knee flexed 90 degrees	Distal to proximal	Bilateral	Not described	7 contours were drawn (total free length of the tendon)	Not consistent
Bedi et al[18]	Standing on a raised level surface with the great toe and	Distal to proximal	Uni/bilateral	25	Achilles: multiple contours (from the disappearance of the	No greater than 5 mm

Copyright © 2019 Wolters Kluwer Health, Inc. Unauthorized reproduction of this article is prohibited.

TABLE 2. Methods of Ultrasound Tissue Characterization Administration *(Continued)*

Author	Patient Position	Direction of the Scan	Side	Window Size	Region of Interest (ROI)	
					Area Analyzed	Interval Between Contours
	knee touching the wall in a standardized lunge position				calcaneus to the musculotendinous junction	
Docking et al[25]	Achilles: standing on a raised level surface with the great toe and knee touching the wall in a standardized lunge position	Achilles tendon: distal to proximal	Uni/bilateral	25	Achilles: multiple contours (from the disappearance of the calcaneus to the musculotendinous junction	No greater than 5 mm
	Patellar tendon: supine position, knee flexed at ~60 degrees.	Patellar tendon: proximal to distal			Patella: over a distance of 3 cm starting from the disappearance of the inferior pole of the patella.	
Docking and Cook[40]	Standing on a raised level surface with the great toe and knee touching the wall in a standardized lunge position	Distal to proximal	Unilateral	25	From disappearance of the calcaneus to the musculotendinous junction	No greater than 5 mm
Wezenbeek et al[32,33]	Prone position with ankle in approximately 5-10 degrees of dorsiflexion	Not described	Bilateral	17	Achilles insertion: 5 contours (from the disappearance of the calcaneus to 2 cm proximal)	5 mm
					Mid-portion: 9 contours (from 2 to 6 cm proximal to the upper border of the calcaneus in a proximal direction)	
Masci et al[28]	Prone position with maximal ankle dorsiflexion	Distal to proximal	Unilateral	25	Not described	
van Ark et al[38]	Supine position with ~100 degrees of knee flexion	Proximal to distal	Unilateral	25	From the apex of the patella to 2 cm distally	No greater than 5 mm
Masci et al[27]	Prone position with maximal ankle dorsiflexion	Distal to proximal	Unilateral	25	Not described	
Rosengarten et al[29]	Standing on a raised level surface with the great toe and knee touching the wall in a standardized lunge position	Distal to proximal	Unilateral	25	From 2 to 4 cm proximal to the upper border of the calcaneus in a proximal direction	5 mm
de Jonge et al[19]	Prone position with feet hanging over the edge and with ankle in approximately 5-10 degrees of dorsiflexion	Not described	Unilateral	9	From 3 to 5 cm proximal to the calcaneal insertion	5 mm
de Jonge et al[20]	Prone position with ankle dorsiflexion of 15 degrees	Proximal to distal	Unilateral	9	5 contours: maximum thickness and 1.5 cm proximal and distal from the segment of maximum thickness	7.5 mm
Docking et al[24]	Participants stood on an elevated platform, with their toes and knee against a wall.	Distal to proximal	Uni/bilateral	25	From the point that the calcaneus disappeared to the musculotendinous junction	Not described
Wong et al[34]	Standing on a raised level surface with the great toe and knee touching the wall	Distal to proximal	Unilateral	25	From the disappearance of the calcaneus to the musculotendinous junction	6 mm
de Vos et al[23]	Prone position with feet hanging over the edge, with dorsiflexion	Not described	Unilateral	9	5 contours: 1.5 cm proximal and distal from the thickest segment (total 3 cm)	
de Vos et al[22]	Prone position with ankle dorsiflexion of 15 degrees	Not described	Unilateral	9	5 contours: 1.5 cm proximal and distal from the thickest segment (total 3 cm)	6 mm
van Schie et al[15]	Prone position with maximal ankle dorsiflexion	Proximal to distal	Unilateral	9	Mean of the thickest part of the tendon and 2 mm proximal and distal	

Copyright © 2019 Wolters Kluwer Health, Inc. Unauthorized reproduction of this article is prohibited.

TABLE 3. Characteristics and Results of the Included Articles

Author/ Year	Design	Subject Characteristics			Pathology (Achilles/ Patellar Tendino-pathy)	Clinical Application	Follow-up	Results	Practical Applications
		Mean Age (yrs)	No. of Subjects (Male: Female)	Sports					
Docking et al, 2018[42]	Prospective cohort	Achilles tendon: 23.9	Achilles tendon: 163	Yes (elite)	Yes and No	Predicting	Single scan	A percentage of DIS above ~2.5% was a significant risk factor for the presence of symptoms at baseline	Quantification of tendon structure using UTC did not enhance the ability to identify athletes who developed symptoms
		Patella tendon: 23.8	Patella tendon: 171					Percentage of DIS showed a weak relationship with severity of symptoms at baseline	
Docking et al, 2018[41]	Prospective Cohort	Achilles tendon: 23.9	Achilles tendon: 149	Yes (elite)	Yes and No	Diagnosis	Single scan	Abnormal tendons contained greater mCSA of AFS compared with normal tendons.	The extent of disorganization in Achilles and patellar tendons does not impact on the presence or severity of clinical symptoms
		Patella tendon: 23.9	Patella tendon: 152					Patellar tendon showed significant difference between players with and without a history of symptoms, and players with and without current symptoms.	
de Sá et al, 2018[21]	Cross-sectional	Statin users: 66	Statin users: 33 (29:4)	Yes (recreational)	No	Diagnosis/ predicting	Single scan	The proportion of echo type I patterns [ST 70 (10)%, CG 74 (13)%] were equivalent in the 2 groups	There is no evidence of a negative statin influence on Achilles tendon structure
		Controls: 63	Controls: 33 (29:4)						
Rudavsky et al, 2018[37]	Prospective cohort	Range from 11 to 18	57 (34:23)	Yes (recreational)	No	Monitoring	2 yrs	Nine percentage of adolescent dancers developed pathology during this study. Only 2 of 5 participants who developed pathology reported pain associated with their tendon	Pathology in the proximal patellar tendon can develop during adolescence

Copyright © 2019 Wolters Kluwer Health, Inc. Unauthorized reproduction of this article is prohibited.

TABLE 3. Characteristics and Results of the Included Articles *(Continued)*

Author/ Year	Design	Subject Characteristics			Pathology (Achilles/ Patellar Tendino-pathy)	Clinical Application	Follow-up	Results	Practical Applications
		Mean Age (yrs)	No. of Subjects (Male: Female)	Sports					
van Ark et al, 2018[39]	Randomized clinical trial	22.7	18 (16:2)	Yes (recreational)	Yes	Monitoring	4 wk	No significant changes on tendon structure were observed after exercise program	Outcomes of treatments for patellar tendinopathy need to be based on clinical findings rather than imaging
Wezenbeek et al, 2018[32]	Prospective cohort	18.03	250 (113:137)	Yes (recreational)	No	Predicting	2 yrs	Structural parameters (echo types) did not predict Achilles tendinopathy.	UTC evaluation should not be the sole basis in predicting the development of tendinopathy.
Waugh et al, 2018[31]	Prospective	30.1	18 (8:10)	Yes (recreational)	No	Monitoring	12 wk	Decrease in echo type I seen after longer rest training compared with shorter rest training. The change in echo type was not related to the change in young's modulus.	UTC can be used to assess tendon response to loading; should preferably be used in combination with other analyses.
Heyward et al, 2017[26]	Randomized crossover	22	21 (12:9)	Yes (recreational)	No	Monitoring	2.7 d	No significant changes on echo types (I-IV) over the period.	Low to moderate loads may be beneficial in the treatment, management or rehabilitation of Achilles tendinopathy
								Significant effects of time were found for echo types III and IV (decrease)	
Rudavsky et al, 2017[36]	Prospective cohort	Ballet dancers from 11 to 18	60 (25:35)	Yes (recreational)	No	Predicting	2 yrs	Tendon disorganization (echo types III + IV) increased; there was a greater increase in the group with abnormalities.	Presence of tendon structure abnormalities was not related to pain, which suggests that development of symptoms involves a complex interplay between a number of factors.
		Control from 21 to 40							

Copyright © 2019 Wolters Kluwer Health, Inc. Unauthorized reproduction of this article is prohibited.

TABLE 3. Characteristics and Results of the Included Articles *(Continued)*

Author/ Year	Design	Subject Characteristics			Pathology (Achilles/ Patellar Tendino-pathy)	Clinical Application	Follow-up	Results	Practical Applications
		Mean Age (yrs)	No. of Subjects (Male: Female)	Sports					
Esmaeili et al, 2017[43]	Prospective cohort	23.7	26 (26:0)	Yes (professional)	No	Monitoring	18 wk	Both limbs and tendons showed increased echo type I.	Regular UTC assessment could find maladaptation to increased training load.
								Training load had inconsistent effects on changes in tendon structure.	
Stanley et al, 2017[30]	Prospective cohort	19.76	21 (9:12)	Yes (semiprofessional)	No	Monitoring	Baseline, 1, 2, and 3 mo	Increase in echo type I. Overall positive adaptation (shift from type II to type I) in tendon structure during season.	UTC can detect changes in tendon structure over a season.
Hernández et al, 2016[35]	Cohort	22.6	20 (20:0)	Yes (professional/ recreational)	No	Diagnosis	Single scan	No significant difference between professional and young players tendon structure.	UTC cannot differentiate symptomatic and asymptomatic cases
								No significant differences on tendon structure of the symptomatic compared with asymptomatic side.	
Bedi et al, 2016[18]	Prospective	32	15 (13:2)	Yes (professional/ semiprofessional)	Yes	Monitoring	25 mo	Decrease in echo types III and IV; increase in echo types I and II.	UTC offers an objective method to evaluate healing of Achilles tendons.
Docking et al, 2016a[25]	Prospective	Achilles tendon: 28.17	Achilles tendon: 66 (63:3)	No/Yes (sedentary/elite athletes)	No specific injury, "patho-logical" and "healthy" tendons	Diagnosis	Single scan	Echo types I and II were significantly lower in the pathological tendon in comparison with normal tendons, and echo types III and IV were significantly increased.	UTC can possibly detect "pathological" tendons, inconclusive is if this results in tendon symptoms.

Copyright © 2019 Wolters Kluwer Health, Inc. Unauthorized reproduction of this article is prohibited.

TABLE 3. Characteristics and Results of the Included Articles *(Continued)*

Author/ Year	Design	Subject Characteristics			Pathology (Achilles/ Patellar Tendino-pathy)	Clinical Application	Follow-up	Results	Practical Applications
		Mean Age (yrs)	No. of Subjects (Male: Female)	Sports					
		Patella tendon: 24.04	Patella tendon: 50 (49:1)						
Docking et al, 2016b[40]	Prospective	23.8	18 (18:0)	Yes (professional)	No	Monitoring	5 mo	Echo type I increased and echo types II-IV decreased, suggesting a tendon improved at the end of the preseason.	UTC can detect changes in the tendon in response to load.
Masci et al, 2016[28]	Prospective cohort	40	18 (14:4)	Yes (recreational/ professional)	Yes	Diagnosis	Single scan	UTC detects tendon disorganization in the medial part of the Achilles tendon.	UTC can complement US and color Doppler by demonstrating disorganized focal medical Achilles tendon structure indicative of plantaris tendon involvement in tendinopathy.
van Ark et al, 2016[38]	Prospective	17.2	41 (30:11)	Yes (recreational)	No	Monitoring	Each day of a 5-d volleyball tournament	No significant changes in tendon structure (echo types I-IV) over the tournament period	Either structure is stable enough, UTC is useless or tournament/time insufficient to bring about change?
								Tendon structure: 54%, 6% echo type I, 42.8% echo type II, 2.2% echo type III, and 0.3% echo type IV.	
Wezenbeek et al, 2017[33]	Cross-sectional	17.9	70 (29:41)	Yes (recreational)	No	Diagnosis	Single scan	More echo type II at insertion than mid-portion.	UTC assesses tendon structure and should be interpreted different depending on location (insertion or mid-portion) of tendon or sex of participant.
								Female tendons contained more echo type II (in insertion and mid-portion than male).	

Copyright © 2019 Wolters Kluwer Health, Inc. Unauthorized reproduction of this article is prohibited.

TABLE 3. Characteristics and Results of the Included Articles *(Continued)*

Author/ Year	Design	Subject Characteristics			Pathology (Achilles/ Patellar Tendino-pathy)	Clinical Application	Follow-up	Results	Practical Applications
		Mean Age (yrs)	No. of Subjects (Male: Female)	Sports					
Masci et al, 2015[27]	Prospective case series	39	8 (7:1)	Yes (recreational)	Yes	Monitoring	6 mo	Increase in echo types I + II and decrease in III + IV at 6 mo.	UTC can assess structural response to treatment
Rosengarten et al, 2015[29]	Prospective	23.8	21 (21:0)	Yes (professional)	Yes	Monitoring	Baseline, 1, 2, and 4 d	Difference in UTC results between groups. There was a transient change (day 2) in tendon structure (disorganization) in those with normal tendons that returned to baseline at day 4.	UTC may be able to detect changes in tendon structure in response to load.
de Jonge et al, 2015a[19]	Case-control	Type 1 diabetics: 23	Type 1: 24 (9: 15)	No/yes (sedentary/ recreational)	No	Predicting	Single scan	UTC shows definite abnormalities in type 2 diabetes patients (possibly also type 1) possibly predictive of tendinopathy.	Screening for high risk of development
		Type 2 diabetics: 49.6	Control type 1: 20 (9:11)						
		Controls for type 1: 24.2	Type 2:24 (15: 9)						
		Controls for type 2: 46.6	Control type 2: 24 (13:11)						
de Jonge et al, 2015b[20]	Prospective	Symptomatic group: 49.7	Symptomatic group: 54 (26: 28)	No/yes (sedentary/ recreational)	Yes	Monitoring	6, 12, 24, and 52 wks.	Difference in echo types between symptomatic and asymptomatic groups.	UTC has no correlation with clinical measure (VISA-A score)
		Asymptomatic group: 51.4	Asymptomatic group: 26 (18: 8)					Tendon structure returns to values of asymptomatic within 24 wks.	
								No relationship however between UTC tendon structure and symptoms. No correlation between VISA-A and UTC.	

Copyright © 2019 Wolters Kluwer Health, Inc. Unauthorized reproduction of this article is prohibited.

TABLE 3. Characteristics and Results of the Included Articles *(Continued)*

Author/ Year	Design	Subject Characteristics			Pathology (Achilles/ Patellar Tendino-pathy)	Clinical Application	Follow-up	Results	Practical Applications
		Mean Age (yrs)	No. of Subjects (Male: Female)	Sports					
Docking et al, 2015[24]	Prospective	Tendinopathy group: 30.3	Tendinopathy group: 21 (20: 1)	Yes (recreational/ professional)	Yes	Diagnosis	Single scan	Significant difference in tendon structure between symptomatic, asymptomatic, and control groups.	UTC might be useful to differentiate between symptomatic and asymptomatic patients and "healthy" subjects.
		Healthy group: 26.8	Healthy group: 6 (5:1)					Asymptomatic tendon is structurally compromised	
Wong et al, 2015[34]	Prospective case–control	Diabetic patient: 37.9	Diabetic group: 7 (5:2)	Yes (recreational)	No	Monitoring	Baseline, 2, and 4 d after the run.	Baseline structure was similar between groups, no structural response to load in either group over 4 days after exercise.	No significant difference in UTC results between diabetics and controls. No transient response to load.
		Control: 32.9	Control group: 10 (4:6)						
de Vos et al, 2012[23]	Prospective clinical trial	46	25 (10:15)	No/yes (sedentary/ recreational)	Yes	Monitoring	Baseline, 2, 8, 16, and 24 wks.	No correlation between VISA-A and UTC. An improvement on echo types I and II was observed without correlation to symptom severity.	UTC assesses tendon structure, although this seems unrelated to symptoms.
de Vos et al, 2011[22]	Randomized clinical trial	PRP group: 49 (8.1)	PRP group: 27 (13:14)	No/yes (sedentary/ recreational)	Yes	Monitoring	Baseline 6, 12, and 24 wk	Improvement in tendon structure after 24 wks.	UTC assesses tendon structure response to treatment(s)
		Saline group: 50 (9.4)	Saline group: 27 (13:14)					No difference in change of echo types between treatment groups.	
van Schie et al, 2010[15]	Case–control	Symptomatic: 44.9	Symptomatic group: 26 (12: 14)	Not described	Yes	Diagnosis	Single scan	Symptomatic tendons showed less echo types I + II than asymptomatic.	UTC useful in monitoring response to treatment.
		Asymptomatic: 43.6	Asymptomatic: 26 (16:10)						

AFS, aligned fibrillar structure; CG, control group; DIS, disorganized tissue structure; mCSA, mean cross-sectional area; ST, Statin group; UTC, ultrasound tissue characterization.

that positioned patients in prone position, different angles of dorsiflexion were used: 5 to 10 degrees,[19,31–33] 15 degrees,[20,22] maximum dorsiflexion,[15,26–28] and neutral position,[41,42] and in 2 studies, this was not specified.[21,23]

In scanning the patellar tendon, patients were positioned sitting with knee flexion of 90 degrees[35] or in supine position in 4 different angles of knee flexion, 60,[40] 90,[36,37] 100,[38,39] or 120 degrees.[41,42]

Copyright © 2019 Wolters Kluwer Health, Inc. Unauthorized reproduction of this article is prohibited.

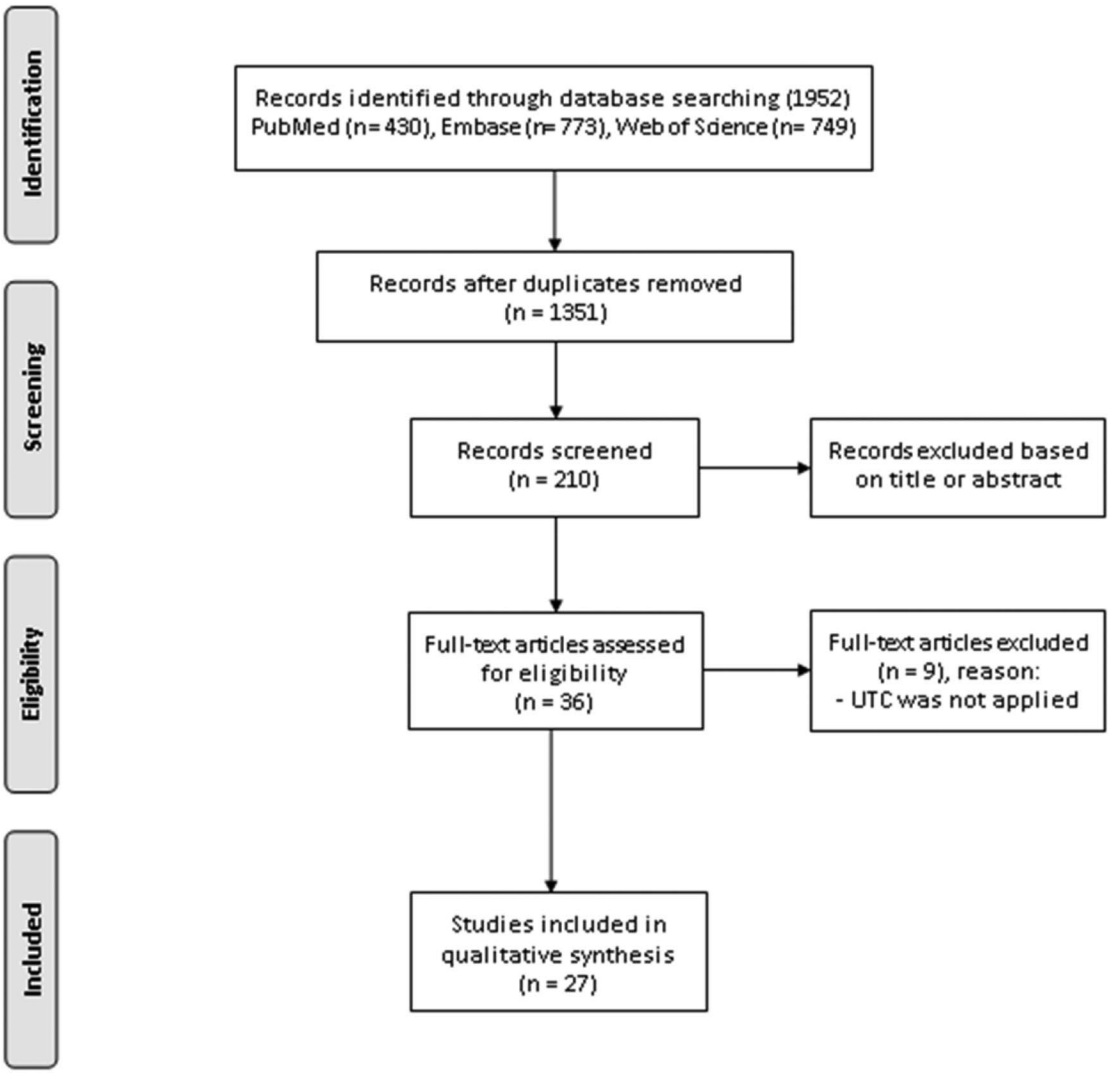

Figure. The flow diagram shows all the steps through the different phases of a systematic review. The figure shows the number of records identified, included and excluded, and the reasons for exclusions.

Most studies that performed a UTC scan of the Achilles tendon performed the scan from distal to proximal.[18,24–30,34,40–43] The patellar tendon was usually scanned from proximal to distal,[36–40] although 1 study scanned from distal to proximal.[35]

The most frequently used window size was 25, N = 16.[18,21,24,25,27–31,34,37–43] Two authors used a window size of 17,[32,33] and 3 authors used a window size of 9.[15,19,20,22,23] One study did not specify the window size used.[35]

Role of Ultrasound Tissue Characterization in Predicting Tendinopathy

Of the 3 studies that investigated the Achilles tendon,[19,32,42] 1 study found that UTC could possibly predict the onset of tendinopathy or symptoms in different populations.[19] However, the prospective studies with the largest sample size determined that UTC structure could not predict the development of tendinopathy in young healthy individuals and elite male Australian football players.[32,42] The studies that investigated the patellar tendon based their results on the amount of disorganized tissue structure (DIS) (echo types III and IV together). One study observed that a higher amount of DIS might increase the risk of developing tendinopathy.[36] Other authors observed that the amount of echo types III and IV at baseline do not predict future symptoms.[42]

Role of Ultrasound Tissue Characterization in Diagnosing Tendinopathy

Ultrasound tissue characterization was used for diagnosis in 8 studies investigating the Achilles tendon[15,21,24,28,33,40–42] and 4 studies assessing the patellar tendon.[35,40–42] Of the AT studies, 2 studies identified that UTC can accurately differentiate between symptomatic and asymptomatic tendons.[15,42] van Schie et al[15] found a diagnostic accuracy of 83% when a threshold of 75% echo types I and II was set to differentiate between asymptomatic (above 75%) and symptomatic (below 75%) tendons. Docking et al[42] observed that a higher percentage of echo types III and IV increases the capacity of UTC to identify subjects with tendinopathy. The same authors found that a percentage above 6% of echo types III and IV was a significant risk factor for the presence of symptoms at baseline measurement.[42] Other authors also observed that symptomatic tendons show significantly higher

Copyright © 2019 Wolters Kluwer Health, Inc. Unauthorized reproduction of this article is prohibited.

percentage of echo types III and IV compared with the asymptomatic tendon.[24,40,41] In addition, to the UTC echo type analysis, some authors also investigated the mean cross-sectional area (mCSA) of the aligned fibrillar structure (AFS) (echo types I and II together) and DIS.[40,41] Docking et al[41] observed that mCSA of AFS in the symptomatic group was similar to the asymptomatic group and the mCSA of DIS was significant higher in the symptomatic group. Docking and Cook[40] observed a significantly higher amount of mCSA of AFS and DIS in the symptomatic group compared with the asymptomatic group.

Masci et al[28] observed that UTC can complement US/Doppler investigation, identifying the involvement of the plantaris tendon in AT cases. One study showed that different factors should be considered when analyzing UTC images (age, sex, tendinopathy location, etc).[33] One study investigated the influence of medication on the Achilles tendon structure and observed no negative effects of statin.[21]

Of the studies investigating patellar tendons, 1 study observed similar findings as found in the patients with AT—a higher percentage of echo types III and IV increases the capacity of the UTC to identify the subjects with tendinopathy.[42] Docking et al[42] showed that a percentage of DIS above 2.5% was a significant risk factor for the presence of symptoms. Other studies found that symptomatic tendons have a higher percentage of echo types III and IV and, consequently, less percentage of echo types I and II compared with asymptomatic subjects.[40,41] When the mCSA was investigated, 2 studies observed that mCSA of AFS and DIS was higher in the symptomatic group compared with the asymptomatic group.[40,41] One study showed that UTC does not differentiate between asymptomatic and symptomatic patellar tendons.[35]

Role of Ultrasound Tissue Characterization in Monitoring Changes in Tendon Structure and/or Tendinopathy

A total of 15 studies used UTC to monitor changes on Achilles or patellar tendons. Of the 12 studies performed a UTC analysis in the Achilles tendon,[18,20,22,23,25–27,29–31,34,43] 6 studies investigated the changes on asymptomatic tendon structure as an adaptation to load,[25,26,29,30,34,43] 4 studies investigated the effect of different treatment modalities on tendon structure,[20,22,23,31] and 2 studies investigated the structural effect of surgical tendinopathy treatment.[18,27] Three studies investigated the patellar tendon,[37–39] 2 investigating the effect of load on asymptomatic tendons,[37,38] and 1 investigating the effect of an exercise treatment.[39] Of the studies that investigated the effect of load on Achilles tendon structure, 4 studies showed a positive adaptation,[25,26,30,43] 1 study showed no changes,[34] and 1 study showed that 2 days after exercise tendon structure showed a transient response and returned to baseline at day 4.[29] Of the studies that assessed tendon structure after either conservative or surgical treatment, 5 studies[18,20,22,23,27] showed that there was an increase in echo type I and a decrease in echo type II, and 1 study showed a decrease in echo type I after training with a short rest period (3 seconds).[31] Regarding the studies investigating the patellar tendon, 1 study showed no significant changes after a 5-day volleyball tournament,[38] 1 study showed no significant changes after conservative treatment,[39] and 1 study showed a tendon maladaptation in adolescent ballet dancers.[37]

DISCUSSION

This study aimed to determine the clinical applicability of UTC in predicting, diagnosing, and monitoring of tendon structure and/or tendinopathy. A systematic review of all literature providing information on the role of UTC in imaging of tendons was conducted, and a total of 27 studies were included, mostly concerning analysis of the Achilles tendon.

Despite the fact that previous research showed that conventional US can predict the onset of Achilles and PT,[14] the results of the studies included in this review suggest that UTC might not predict the development of AT when the whole tendon is contoured and a percentage threshold is set; perhaps, this is a result of the methods of UTC analysis because previous studies show US is predictive of new symptoms.[14] Several studies assessed the total volume of the Achilles tendon, whereas studies using conventional US focused specifically on pathological regions.[14] In addition, the use of window size of 25 and lack of information regarding contour distance may also influence the image interpretation, as important (future) pathology may be missed. Regarding the results for the patellar tendon, the use of UTC to predict the development of future symptoms is inconclusive when based on percentage of echo types III and IV.[15] However, it may be important to consider the level of healthy tissue using echo types I and II.[42] To be able to predict future symptomatic pathology, however, UTC images of healthy controls of which some eventually develop tendinopathy are required. Given the relatively low incidence of AT and PT in the general population, the required subject number is very difficult to achieve; this explains the low number of predictive UTC studies. Of the included studies attempting to predict tendinopathy using UTC, different study designs and populations were used; this makes comparing the results of these studies difficult because of heterogeneity. More uniform studies into the predictive value of UTC are needed.

The results of this review showed that UTC might be able to provide additional diagnostic data in patients with AT; however, UTC seems to offer little benefit over and above conventional imaging for the PT.[2,13,44,45] Pathological Achilles tendons show a lower percentage of echo types I and II and, consequently, a higher percentage of echo types III and IV.[28,33,40,46] However, despite the presence of disorganized structure, UTC alone cannot differentiate between asymptomatic and symptomatic tendons. A possible explanation for these findings might be the fact that pathology may develop before the presence of clinical symptoms.[14,47] A previous study using UTC which showed that tendon structure of the contralateral, asymptomatic, tendon is also compromised corroborates with this explanation.[24] In addition to that, some authors suggest that tendons with higher percentage of echo types III and IV (DIS structure) would also present a higher area of AFS that allows the tendon to function without presenting symptoms. However, the number of studies using UTC for tendinopathy diagnosis is still low (N = 9), and the absence of reference (gold standard) values for the UTC echo types makes it difficult to use this tool for diagnosing tendinopathy.

In addition to providing additional diagnostic information in AT, UTC shows potential in its ability to monitor the effect of load/treatment on Achilles and patellar tendon structure. Ultrasound tissue characterization seems to be able to detect subtle changes on tendon structure as a result of loading. However, the use of this tool to monitor the effect of

Copyright © 2019 Wolters Kluwer Health, Inc. Unauthorized reproduction of this article is prohibited.

a rehabilitation protocol is not clear yet, especially given that the association between UTC echo types and the clinical outcome is inconclusive. This lack of association is also observed for the conventional imaging outcomes, and the tendon might need to be investigated in a long-term follow-up to observe the (changes on) tendon structure after treatment.[44,48]

Unlike conventional techniques, UTC provides objective information on tendon structure that can potentially be used in multiple phases of tendinopathy management (predicting, diagnosing, and monitoring). These objective parameters can be used to detect (mal)adaptation to load and/or treatment and provide quantifiable information in the diagnostic and monitoring phases. For example, UTC is an interesting imaging tool to be correlated with the continuum model.[49] This model proposes that tendon pathology occurs in several phases, and using UTC, it might be possible to identify the current phase and the tendon's response to the load/treatment performed. More research into adaptive and maladaptive responses to loading and treatment however is required. Athletes should preferably be followed longitudinally to determine specific thresholds for pathology based on echo types. In addition, this imaging pathology should be correlated to the clinical picture and to the golden standard, histology, to conclude on UTC's role in diagnosing injuries specifically. The latter would require correlations between human tendon biopsies and UTC, to substantiate the true pathology seen by echo types. Previous research investigated these correlations in the equine superficial digital flexor and showed that the UTC is a valid tool to quantitatively measure tendon structural integrity.[16]

Limitations and Future Directions

A limitation of this review is the lack of methodological quality assessment of the included studies. We opted for a narrative, descriptive, approach to this review. In addition, the included studies showed to be heterogeneous in methods, designs, and aims enabling data pooling.

In contrast to the heterogeneity in study design and methods, the included studies tended to focus on the same tendinopathy, that is, mid-portion AT; however, this matches the incidence rates in the general population.[4,5] The lack of studies on PT makes conclusions about UTC's potential in tendinopathies difficult to determine. The results of our review also showed that many of the same authors contributed to the scientific literature concerning UTC, potentially increasing bias in methodologies and interpretational expertise. We therefore believe more authors should investigate the potential of UTC, taking various populations into consideration: for example, subjects with different level of activity, larger range of age, and, again, with different locations of tendinopathy.

Ultrasound Tissue Characterization Standard Methodology

Because the results show a wide variation in the UTC methods applied, no standard synthesized recommendations for UTC use based can be made.

Standardization of the UTC methodology is necessary to ensure homogeneity of scientific results and facilitate analyses and comparisons. Furthermore, this standard methodology can be applied in clinical practice. The standard methodology regarding UTC scanning should include patient positioning, direction of the scan, and tendon side, and the parameters for the imaging analysis should include window size, area of interest, and interval between the contours. Based on the methodology used in the studies included in this review and on the expertise of the authors concerning UTC equipment, this article proposes such a standard methodology for UTC scanning and imaging analysis for Achilles and patellar tendons.

The proposed standardized method is shown in Table 4.

Regarding the scanning of unilateral or bilateral, the included studies show that in a research setting, it is sufficient to scan unilaterally. However, because the contralateral, asymptomatic tendon often shows a compromised structure,[24] it is recommended to scan bilaterally in clinical practice. This allows clinicians to detect abnormalities that might increase the risk of future tendinopathy.[14] Similar to the studies included in this review, we recommend patients be positioned according to the authors' preference in scanning the Achilles tendon, as no superiority of a single position has been shown. More important than the position is a maximum level of tension on the Achilles tendon, and this requires scanning in maximum dorsiflexion. In scanning the patellar tendon, a supine position with the knee flexed 90 to 100 degrees is recommended, allowing for the necessary tendon tension. In line with the studies included in this review, we recommend the Achilles tendon is scanned distal to proximal and patellar tendon proximal to distal because this ensures that the proximal calcaneus and apex of the patella are identified before scanning; both of these landmarks are important for identifying the exact position along the tendons. This improves objectivity and is critical for accurate repeated measurements.

Regarding imaging analysis, most studies included in this review used the window size of 25. However, based on the

TABLE 4. Recommendations for UTC Administration and Analysis

Patient Position	Direction of the Scan	Side	Window Size	Area of Interest (ROI)	Interval Between Contours
Achilles tendon					
Patient prone with ankle in maximum dorsiflexion	Distal to proximal	Bilateral	9 or 17	Insertion—from the upper border of the calcaneus to 2 or 3 cm proximal.	No greater than 5 mm
				Mid-portion—from 2 cm proximal to the upper border of the calcaneus to 6 cm proximal. Minimum of a 2-cm ROI.	
Patellar tendon					
Patient supine with knee in flexion between 90 and 100 degrees	Proximal to distal	Bilateral	9 or 17	From the patella appendix to 3 cm distally.	No greater than 5 mm

Copyright © 2019 Wolters Kluwer Health, Inc. Unauthorized reproduction of this article is prohibited.

UTC algorithm,[33] using window sizes of 9 or 17 allows images to be analyzed in greater detail.[33] More sensitive settings might be used to draw accurate conclusions. Therefore, we recommend that UTC images should be analyzed using window size of 17 or 9. Moreover, based on the studies included in this review, we also suggest that contours should be drawn no greater than 5 mm apart because contouring at greater lengths can lead to false interpolation of the tendon either including tissue external to the tendon or missing tendon tissue, thereby giving false results.

Regarding the tendon area selected for analysis, 3 different sites of the Achilles tendon can be analyzed depending on the zone of pathology: (1) full length (from the disappearance of the calcaneus to the musculotendinous junction), (2) insertion (from the disappearance of the calcaneus to 2 cm proximal), and (3) mid-portion (from 2 to 6 cm proximal to the upper border of the calcaneus in a proximal direction). However, as the insertion and mid-portion show a different distribution of echo types,[33] and it is believed that insertional and mid-portion AT are distinct clinical and tendon pathologies,[50] we recommend analyzing the insertion and mid-portion separately. For the patellar tendon images, since tendinopathy is frequently observed in the inferior pole of the patella,[51] the analysis of the proximal area (from apex to 3 cm distally) is recommended.

CONCLUSION AND RECOMMENDATIONS

The results of this review showed a potential clinical role for UTC in monitoring changes in tendon structure and/or tendinopathy. The echo types that UTC provides might be interpreted in the context of multiple outcomes to guide the athlete to optimal loading and the patient to adequate recovery. In conclusion, UTC analysis seems to have an important potential for monitoring changes in tendon structure and/or tendinopathy, but further studies need to consider the methodology they use and its exact clinical interpretation. Additional research is needed validating the use of UTC in the human tendon, and more research is needed investigating the UTC potential in predicting and diagnosing tendinopathy.

References

1. Maffulli N, Wong J. Rupture of the Achilles and patellar tendons. *Clin Sports Med*. 2003;22:761–776.
2. Malliaras P, Barton CJ, Reeves ND, et al. Achilles and patellar tendinopathy loading programmes: a systematic review comparing clinical outcomes and identifying potential mechanisms for effectiveness. *Sport Med*. 2013;43:267–286.
3. Tan SC, Chan O. Achilles and patellar tendinopathy: current understanding of pathophysiology and management. *Disabil Rehabil*. 2008;30:1608–1615.
4. de Jonge S, van den Berg C, de Vos RJ, et al. Incidence of midportion Achilles tendinopathy in the general population. *Br J Sports Med*. 2011; 45:1026–1028.
5. Albers IS, Zwerver J, Diercks RL, et al. Incidence and prevalence of lower extremity tendinopathy in a Dutch general practice population: a cross sectional study. *BMC Musculoskelet Disord*. 2016;17:16.
6. Janssen I, van der Worp H, Hensing S, et al. Investigating Achilles and patellar tendinopathy prevalence in elite athletics. *Res Sports Med*. 2018; 26:1–12.
7. Maffulli N, Kader D. Tendinopathy of tendo Achillis. *J Bone Joint Surg Br*. 2003;84:1–8.
8. Rudavsky A, Cook J. Physiotherapy management of patellar tendinopathy (jumper's knee). *J Physiother*. 2014;60:122–129.
9. Maffulli N. Current concepts review—rupture of the Achilles tendon. *J Bone Joint Surg*. 1999;81:1019–1036.
10. Józsa L, Kvist M, Bálint BJ, et al. The role of recreational sport activity in Achilles tendon rupture. A clinical, pathoanatomical, and sociological study of 292 cases. *Am J Sports Med*. 1989;17:338–343.
11. Kannus P, Jozsa L. Histopathological changes preceding spontaneous rupture of a tendon: a controlled study of 891 patients. *J Bone Joint Surg Am*. 1991;73:1507–1525.
12. Kaux JF, Forthomme B, Goff CL, et al. Current opinions on tendinopathy. *J Sports Sci Med*. 2011;10:238–253.
13. Drew BT, Smith TO, Littlewood C, et al. Do structural changes (eg, collagen/matrix) explain the response to therapeutic exercises in tendinopathy: a systematic review. *Br J Sports Med*. 2014;48:966–972.
14. McAuliffe S, McCreesh K, Culloty F, et al. Can ultrasound imaging predict the development of Achilles and patellar tendinopathy? A systematic review and meta-analysis. *Br J Sports Med*. 2016;50:1516–1523.
15. van Schie HTM, de Vos RJ, de Jonge S, et al. Ultrasonographic tissue characterisation of human Achilles tendons: quantification of tendon structure through a novel non-invasive approach. *Br J Sports Med*. 2010;44:1153–1159.
16. van Schie HT, Bakker EM, Jonker AM, et al. Efficacy of computerized discrimination between structure-related and non-structure-related echoes in ultrasonographic images for the quantitative evaluation of the structural integrity of superficial digital flexor tendons in horses. *Am J Vet Res*. 2001;62:1159–1166.
17. Moher D, Shamseer L, Clarke M, et al. Preferred reporting items for systematic review and meta-analysis protocols (PRISMA-P) 2015 statement. *Syst Rev*. 2015;4:1.
18. Bedi HS, Jowett C, Ristanis S, et al. Plantaris excision and ventral paratendinous scraping for Achilles tendinopathy in an athletic population. *Foot Ankle Int*. 2016;37:386–393.
19. de Jonge S, Rozenberg R, Vieyra B, et al. Achilles tendons in people with type 2 diabetes show mildly compromised structure: an ultrasound tissue characterisation study. *Br J Sports Med*. 2015;49:995–999.
20. de Jonge S, Tol JL, Weir A, et al. The tendon structure returns to asymptomatic values in nonoperatively treated Achilles tendinopathy but is not associated with symptoms. *Am J Sports Med*. 2015;43:2950–2958.
21. de Sá A, Hart DA, Khan K, et al. Achilles tendon structure is negatively correlated with body mass index, but not influenced by statin use: a cross-sectional study using ultrasound tissue characterization. *PLoS One*. 2018;13:1–9.
22. de Vos RJ, Weir A, Tol JL, et al. No effects of PRP on ultrasonographic tendon structure and neovascularisation in chronic midportion Achilles tendinopathy. *Br J Sports Med*. 2011;45:387–392.
23. de Vos RJ, Heijboer MP, Weinans H, et al. Tendon structure's lack of relation to clinical outcome after eccentric exercises in chronic midportion Achilles tendinopathy. *J Sport Rehabil*. 2012;21:34–43.
24. Docking SI, Rosengarten SD, Daffy J, et al. Structural integrity is decreased in both Achilles tendons in people with unilateral Achilles tendinopathy. *J Sci Med Sport*. 2015;18:383–387.
25. Docking SI, Rosengarten SD, Cook J. Achilles tendon structure improves on UTC imaging over a 5-month pre-season in elite Australian football players. *Scand J Med Sci Sport*. 2016;26:557–563.
26. Heyward OW, Rabello LM, van der Woude L, et al. The effect of load on Achilles tendon structure in novice runners. *J Sci Med Sport*. 2017:21:661–665.
27. Masci L, Spang C, van Schie HT, et al. Achilles tendinopathy—do plantaris tendon removal and Achilles tendon scraping improve tendon structure? A prospective study using ultrasound tissue characterisation. *BMJ Open Sport Exerc Med*. 2015;1:e000005.
28. Masci L, Spang C, van Schie HT, et al. How to diagnose plantaris tendon involvement in midportion Achilles tendinopathy—clinical and imaging findings. *BMC Musculoskelet Disord*. 2016;17:97.
29. Rosengarten SD, Cook JL, Bryant AL, et al. Australian football players' Achilles tendons respond to game loads within 2 days: an ultrasound tissue characterisation (UTC) study. *Br J Sports Med*. 2015;49:183–187.
30. Stanley LE, Lucero A, Mauntel TC, et al. Achilles tendon adaptation in cross-country runners across a competitive season. *Scand J Med Sci Sport*. 2018;28:303–310.
31. Waugh CM, Alktebi T, de Sa A, et al. Impact of rest duration on Achilles tendon structure and function following isometric training. *Scand J Med Sci Sport*. 2018;28:436–445.
32. Wezenbeek E, Willems T, Mahieu N, et al. The role of the vascular and structural response to activity in the development of Achilles tendinopathy: a prospective study. *Am J Sports Med*. 2018;46:947–954.
33. Wezenbeek E, Mahieu N, Willems TM, et al. What does normal tendon structure look like? New insights into tissue characterization in the Achilles tendon. *Scand J Med Sci Sport*. 2017;27:746–753.
34. Wong AMY, Docking SI, Cook JL, et al. Does type 1 diabetes mellitus affect Achilles tendon response to a 10 km run? A case control study. *BMC Musculoskelet Disord*. 2015;16:345.

Copyright © 2019 Wolters Kluwer Health, Inc. Unauthorized reproduction of this article is prohibited.

35. Hernández G, Domínguez D, Moreno J, et al. Patellar tendon analysis by ultrasound tissue characterization; comparison between professional and amateur basketball players. *Asymptomatic versus symptomatic*. 2017;52: 45–52.
36. Rudavsky A, Cook J, Magnusson SP, et al. Characterising the proximal patellar tendon attachment and its relationship to skeletal maturity in adolescent ballet dancers. *Muscles Ligaments Tendons J*. 2017;7: 306–314.
37. Rudavsky A, Cook JL, Docking S. Proximal patellar tendon pathology can develop during adolescence in young ballet dancers—a 2 year longitudinal study. *Scand J Med Sci Sports*. 2018;28:2035–2041.
38. van Ark M, Docking SI, van den Akker-Scheek I, et al. Does the adolescent patellar tendon respond to 5 days of cumulative load during a volleyball tournament? *Scand J Med Sci Sport*. 2016;26:189–196.
39. van Ark M, Rio E, Cook J, et al. Clinical improvements are not explained by changes in tendon structure on UTC following an exercise program for patellar tendinopathy. *Am J Phys Med Rehabil*. 2018;97: 708–714.
40. Docking SI, Cook J. Pathological tendons maintain sufficient aligned fibrillar structure on ultrasound tissue characterization (UTC). *Scand J Med Sci Sport*. 2016;26:675–683.
41. Docking SI, Girdwood MA, Cook J, et al. Reduced levels of aligned fibrillar structure are not associated with Achilles and patellar tendon symptoms. *Clin J Sport Med*. 2018. doi:10.1097/JSM.0000000000000644. [Epub ahead of print.]
42. Docking SI, Rio E, Cook J, et al. Quantification of Achilles and patellar tendon structure on imaging does not enhance ability to predict self-reported symptoms beyond grey-scale ultrasound and previous history. *J Sci Med Sport*. 2018;22:145–150.
43. Esmaeili A, Stewart AM, Hopkins WG, et al. Effects of training load and leg dominance on Achilles and patellar tendon structure. *Int J Sports Physiol Perform*. 2017;12:S2122–S2126.
44. Dams OC, Reininga IHF, Gielen JL, et al. Imaging modalities in the diagnosis and monitoring of Achilles tendon ruptures: a systematic review. *Injury*. 2017;48:2383–2399.
45. Malliaras P, Cook J, Purdam C, et al. Patellar tendinopathy: clinical diagnosis, load management, and advice for challenging case presentations. *J Orthop Sport Phys Ther*. 2015;45:887–898.
46. Cook JL, Rio E, Purdam CR, et al. Revisiting the continuum model of tendon pathology: what is its merit in clinical practice and research? *Br J Sport Med*. 2016;50:1187–1191.
47. Visnes H, Tegnander A, Bahr R. Ultrasound characteristics of the patellar and quadriceps tendons among young elite athletes. *Scand J Med Sci Sport*. 2015;25:205–215.
48. Rabello LM, Akker-scheek I van den Akker-Scheek I, et al. Association between clinical and imaging outcomes after therapeutic loading exercise in patients diagnosed with Achilles or patellar systematic review. *Clin J Sport Med*. 2018. doi:10.1097/JSM.0000000000000624. [Epub ahead of print.]
49. Cook JL, Purdam CR. Is tendon pathology a continuum? A pathology model to explain the clinical presentation of load-induced tendinopathy. *Br J Sports Med*. 2009;43:409–416.
50. Knobloch K, Kraemer R, Lichtenberg A, et al. Achilles tendon and paratendon microcirculation in midportion and insertional tendinopathy in athletes. *Am J Sports Med*. 2006;34:92–97.
51. Pearson SJ, Stadler S, Menz H, et al. Immediate and short-term effects of short- and long-duration isometric contractions in patellar. *Tendinopathy*. 2018. doi:10.1097/JSM.0000000000000625. [Epub ahead of print.]

Copyright © 2019 Wolters Kluwer Health, Inc. Unauthorized reproduction of this article is prohibited.